

June 2016

## Case Study on Patient A26 Using Nisus Negative Pressure Wound Therapy System

### Wound Type

Non-healing surgical  
Location: Abdomen wall  
Date Wound Acquired: 4/21/16  
Patient Age: 58

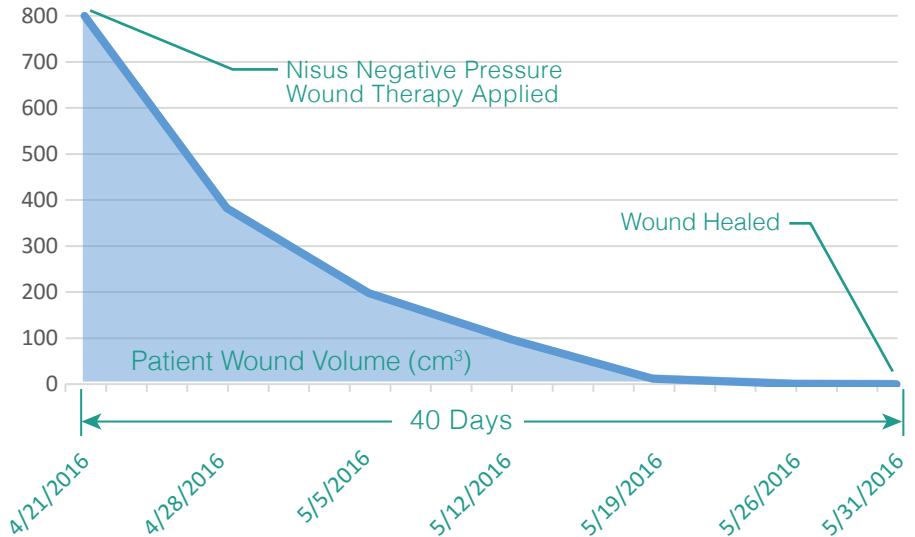
### History and Physical

58 year old male presented to the ED with abdominal pain. CT scan showed a perforation of the small bowel, emergency surgery performed.

The fascia was closed during the procedure and the Nisus NPWT platform applied immediately post-operative.

### Past Medical History

Patient has history of DM, obesity, CHF, COPD, and 25 pack per year cigarette smoker.



### Initial Findings

Post-operative wound measurements were length of 16 cm, width of 10 cm, and depth of 5 cm. The wound pre-operatively is 100% pink and with minimal serous drainage. The Nisus NPWT platform was applied at this time.

### Course of Treatment

The Nisus NPWT was applied immediately post operatively to the mid abdominal surgery on 4/21/16. The primary modality of treatment for this wound was the Nisus NPWT platform. The patient required one excisional debridement on 5/5/16, secondary to 10% of the wound bed contained firmly adherent slough.

The Nisus NPWT was discontinued on 5/31/16 and the wound was completely closed on 6/7/16.

Date	Modality of Treatment	Weeks in Treatment	Length (cm)	Width (cm)	Depth (cm)	Volume (cm)
4/21/2016	Nisus NPWT platform initiated	0	16	10	5	800.00
4/28/2016	Nisus NPWT platform	1	13	7	4.2	382.20
5/5/2016	Nisus NPWT platform and debridement	2	11	5	3.6	198.00
5/12/2016	Nisus NPWT platform	3	8.1	4.3	2.8	97.52
5/19/2016	Nisus NPWT platform	4	4.2	2.4	1.2	12.10
5/26/2016	Nisus NPWT platform	5	1.8	1.1	0.3	0.59
5/31/2016	NPWT discontinued and contact layer applied	6	0.6	0.2	0.1	0.01
6/07/2016	Wound completely healed	7	0	0	0	0.00